

Cochlear Implant Surgical Technique: Our Experience

Milind Vasant Kirtane¹ Kashmira Prakash Chavan²

¹Department of ENT, P. D. Hinduja National Hospital, Mumbai, Maharashtra, India

²Department of ENT, Dr. L. H. Hiranandani Hospital, Powai, Mumbai, Maharashtra, India

Address for correspondence Kashmira Prakash Chavan, DNB (ENT), MBBS, 704, Sun Heights, Near Sun City Complex, Adi Sankaracharya Marg, Powai, Mumbai 400076, Maharashtra, India (e-mail: kashuc@yahoo.com).

Ann Otol Neurotol ISO 2018;1:7–10

Abstract

Introduction Different surgical approaches have been adopted for cochlear implantation, with cortical mastoidectomy–posterior tympanotomy being the most commonly followed technique.

Method In this article, we describe the surgical technique for cochlear implant followed at our center, which has been successfully implemented in more than 2,500 cochlear implant surgeries. Cochlear implant surgery using the cortical mastoidectomy–posterior tympanotomy technique has been performed in more than 2,500 cases with some modifications to the original technique over a period of time.

Results In spite of not using tie-down holes and securing down the receiver–stimulator with sutures, no cases of receiver–stimulator displacement or outward electrode migration have been noted with the current technique of creating a snug-fitting subperiosteal pocket along with a hook for the electrode array.

Conclusion Adhering to a strict intraoperative surgical protocol plays an extremely important role in carrying out successful cochlear implant surgeries with minimal complications.

Keywords

- ▶ cochlear implants
- ▶ surgical technique
- ▶ posterosuperior musculoperiosteal flap

Introduction

Cochlear implant surgery is now being performed for more than 40 years. Different surgical approaches have been adopted for cochlear implantation, with cortical mastoidectomy–posterior tympanotomy being the most commonly followed technique.¹ In this article, we describe the surgical technique for cochlear implant followed at our center and the changes that we incorporated over the years.

Method

The cochlear implant program at P. D. Hinduja Hospital and Medical Research Centre, Mumbai, India, started in 1996. Since then, more than 2,500 cochlear implant surgeries have been performed under this program.

Surgical Technique

The surgery is performed under general anesthesia. After cleaning and draping, the postaural area is infiltrated with adrenaline in saline (1:80,000 dilution). Before taking the

skin incision, the position of the well is marked through the skin with an 18-gauge needle dipped in methylene blue using the company provided measuring templates. A 4- to 5-cm curvilinear postaural incision is taken. The superior end of the incision curves slightly anterior to prevent overlapping with the receiver–stimulator and with the musculoperiosteal incision taken later. Tiny pieces of connective tissue are harvested (used later to seal the cochleostomy). The anterior skin edge of the incision is undermined. A narrow anteriorly based musculoperiosteal flap is elevated (parallel to and below the undermined anterior skin edge). This helps in providing a tension-free suturing during closure. A posterosuperiorly based musculoperiosteal flap is then elevated (▶ **Fig. 1**). The anterior incision of this flap is taken such that it does not directly lie under the skin incision. A snug-fitting subperiosteal pocket for the receiver–stimulator is created below the flap (dimension confirmed using the metal template for the receiver–stimulator). An anterior subperiosteal tunnel is created for the ground electrode (for nucleus cochlear implants). Cortical mastoidectomy is then performed. A slight overhang is kept at the edges of the mastoid cavity. A specially designed

DOI <https://doi.org/10.1055/s-0037-1608753>.

Copyright © 2018 Indian Society of Otolaryngology

License terms



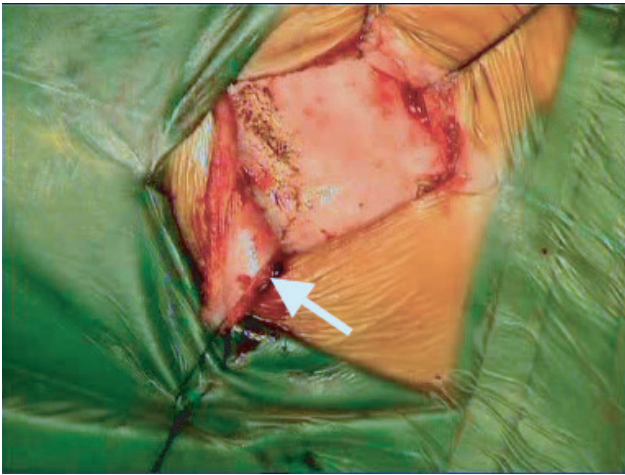


Fig. 1 Image showing posterosuperiorly raised musculoperiosteal flap (white arrow).

retractor (Kirtane's retractor, ► **Fig. 2**) is used to retract the musculoperiosteal flap while drilling the well for the receiver-stimulator. The serrated edges of the retractor provide a good grip over the bone. The concave surface of the retractor provides adequate space for the burr and handpiece and prevents obstruction of the field of vision when drilling. It protects the musculoperiosteal flap from inadvertent damage and tearing by the burr (► **Fig. 3**). It also has a provision to connect a light source and a suction tube. A version of the retractor without the attachments for light source and suction has also been designed. The provided templates are used to confirm the adequacy of well dimensions. In cases where the bone thickness is very less, a thin central island of bone is maintained in the floor of the well, so that the receiver-stimulator does not directly rest on the dura. The position of the exit channel for the electrode array is marked with the help

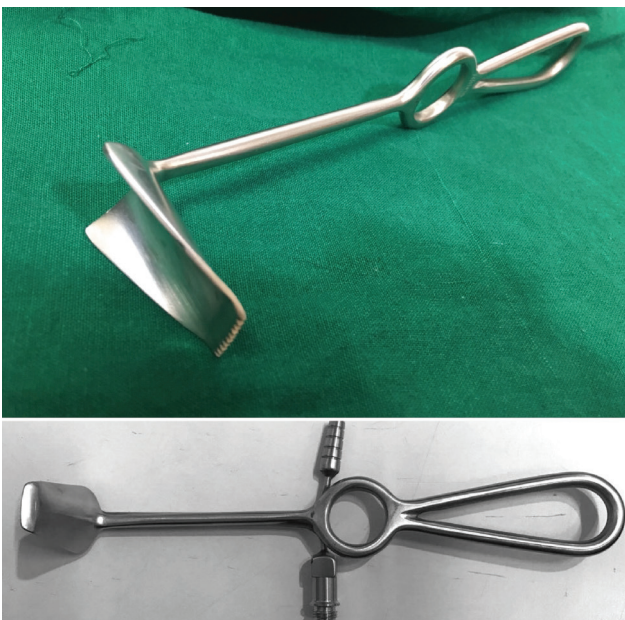

Fig. 2 Kirtane's retractor (without and with provision for light source and suction attachment).

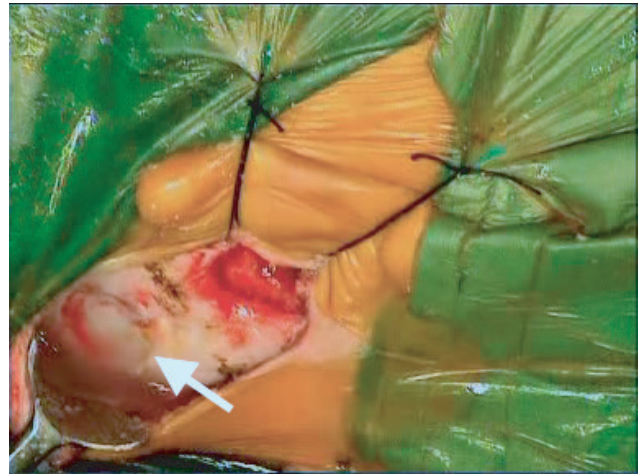

Fig. 3 Kirtane's retractor being used to retract and protect the posterosuperiorly-based musculoperiosteal flap while drilling the well (white arrow).

of the templates. The floor and sides of the well and the channel for the electrodes are smoothed with a diamond burr. A hook is created just proximal to the point where the electrode array dips into the mastoid cavity (► **Fig. 4**). This hook helps in holding the electrode array in place and helps prevent outward migration of the array. Once the short process of the incus is identified, the posterior canal wall is thinned out. The facial nerve is identified and a posterior tympanotomy is drilled using the short process of the incus, chorda tympani nerve, and facial nerve as landmarks. The round window is identified. The round window membrane is incised using a 22-gauge needle (round window approach), a separate cochleostomy is created anteroinferior to the round window (cochleostomy approach), or a cochleostomy is made in continuity with the anteroinferior edge of the round window (extended round window approach). Hydrocortisone is injected into the cochlear lumen via the cochleostomy. The receiver-stimulator is then fixed into the well in the subperiosteal pocket created. No tie-down holes or sutures are used to secure the implant. The ground electrode (for nucleus

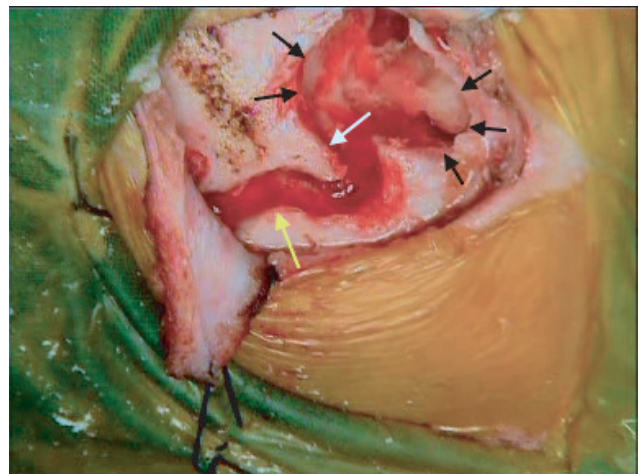


Fig. 4 Image showing electrode exit channel (yellow arrow), hook to hitch electrode array (white arrow), and overhang over the edges of the mastoid cavity (black arrows).

cochlear implant) is placed in the anterior subperiosteal tunnel in direct contact with the bone. The active electrode array is gradually introduced into the cochlear lumen via the round window opening or the cochleostomy. The cochleostomy is sealed with connective tissue harvested earlier. The electrode array is hitched under the hook created in the channel for the electrode array (►Fig. 5). Closure is then performed in layers. The posterosuperiorly based flap is approximated to the small anterior flap to provide a complete cover for the device without any tissue tension at the closure site. Skin closure is performed with subcuticular 3–0 Vicryl sutures.

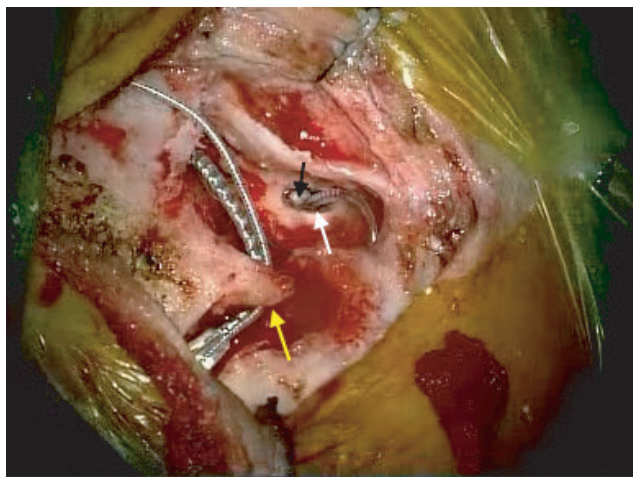


Fig. 5 Image showing electrode array introduced into the cochleostomy via posterior tympanotomy (white arrow), connective tissue seal around cochleostomy (black arrow), and electrode array hitched under the hook (yellow arrow).

Intraoperative impedances and neural response telemetry/neural response imaging are performed to confirm functioning of the implant. Intraoperative C-arm imaging is also performed to confirm accurate electrode positioning. X-ray (transorbital/modified Stenver's view) is performed before the patient is discharged from the hospital. Device switch-on is performed 2 weeks postsurgery once the postaural wound heals.

Discussion

The technique for cochlear implant surgery described has been performed in more than 2,500 surgeries till date. The postaural incision length is kept at between 4 and 5 cm, which is just enough to provide adequate exposure and, at the same time, helps avoid excessive stretching of tissues. If a very small postaural incision is taken, it may lead to squeezing of the receiver–stimulator packet, while introducing it through the incision, and a risk of squeezing out of the magnet from the receiver–stimulator packet. This can lead to magnet displacement in the future. An incision, that is too small, may lead to excessive tissue retraction and stretching that may interfere with the blood supply and hence in wound healing. Large incisions have been reported to be associated with higher rates of device extrusions.¹ The skin incision curves slightly anterior toward its superior end so that it does

not directly overlap the receiver–stimulator. This helps prevent immediate direct exposure of the receiver–stimulator in cases of wound breakdown. We made our modification in the surgical technique by creating a narrow strip of anteriorly based flap after skin edge undermining. This flap, when approximated with the anterior edge of the posterosuperiorly based musculoperiosteal flap, provides a tension-free closure, thus preventing tearing of the musculoperiosteal flap, especially in cases of thin flaps in young children. The posterosuperiorly based flap provides a complete cover for the receiver–stimulator. The anterior incision for this flap is taken such that the skin incision does not directly overlap it. This helps prevent immediate exposure of the implant in case of skin incision infection and wound breakdown.

Various methods of fixing the receiver–stimulator have been practiced. These include fixing the device with titanium screws on either side,² using a polypropylene mesh over the device and securing the mesh with titanium screws,³ using ionomeric cement,⁴ securing the proximal portion of the electrode by placing it in a drilled-out groove connecting the well and mastoid,⁵ or sewing the periosteum together over the implant.⁶ Balkany et al have described the temporalis pocket technique without drilling a well or fixation of any type.⁷

In our initial cases, we followed the procedure of drilling tie-down holes and using sutures to secure the implant. However, there is a risk of occurrence of cerebrospinal fluid (CSF) leak, or bleeding from the dural vessels when doing this, especially in children, where the bone thickness is very less. The suture material/tie-down tape may dig into the receiver–stimulator casing, leading to damage, and may also act as a nidus for infection and potential biofilm formation.¹ We therefore abandoned the practice of drilling tie-down holes and tying down the implant; instead, we only created a snug-fitting subperiosteal pocket and a perfectly fitting well, along with a small hook positioned just proximal to the junction of the mastoid cavity edge and the electrode channel. The musculoperiosteal flap also provides a tight cover for the receiver–stimulator, thus preventing device displacement. There have been no cases of displacement of the receiver–stimulator with this technique so far. Balkany and Telischi have described the split bridge technique of using the incus buttress as a fixation point for the electrode to prevent electrode migration.⁸ Cohen and Kuzma used a titanium clip to secure the electrode to the incus buttress.⁹ Other techniques, such as tightly packing the cochleostomy with tissue, placing a coil of electrode against the tegmen mastoideum, and using precurved electrode arrays, have been used to prevent electrode migration.¹⁰

When drilling the cortical mastoidectomy, we maintain an overhang at the edges of the mastoid cavity, which helps hold the extra coils of the electrode array wire in place, thus preventing the array from bouncing out. When the electrode exit channel is drilled, we create a small hook positioned just proximal to the junction of the mastoid cavity edge and the electrode channel. This hook acts as a hitch for the electrode array and helps in stabilizing it post insertion, thus preventing outward electrode migration.

When drilling the posterior tympanotomy, we recommend identifying the position of the bony facial canal, as this minimizes the chances of a facial nerve injury.

The size of the diamond burr (0.8–1.0 mm) for cochleostomy is chosen depending on the thickness of the electrode array to be introduced. Once the endosteum is exposed, the cochlear lumen is opened, with a right-angle pick or a circular disc, to prevent bone dust from entering the cochlear lumen and create a soft opening. For round window insertions, the round window membrane is incised with a bent 22-gauge needle on a syringe or with a curved pick. After the cochleostomy is created or round window is incised, hydrocortisone is injected into the cochlear lumen. Steroid injection lumen helps in residual hearing preservation, as well as in flushing out any bone dust or blood that may have entered into the cochlear lumen during drilling. Once the electrode array is introduced into the cochlear lumen, the cochleostomy is sealed with connective tissue (harvested earlier). This may prevent introduction of infection into the cochlear lumen. Sealing the cochleostomy, along with hitching of the array at the hook created in the electrode channel, also reduces the chances of electrode migration.

Closure is performed in layers. The posterosuperiorly based flap is approximated to the small anterior flap. This helps in achieving a complete cover for the receiver–stimulator without any tension at the wound edges, thus minimizing chances of flap breakdown and risk of device infection. Subcuticular skin closure is performed with a 3–0 Vicryl suture. Because subcuticular absorbable sutures do not need removal, it helps avoid the discomfort of suture removal especially in children.

Intraoperative electrical testing of the implant (neural response telemetry/neural response imaging and impedance) is always performed to confirm proper functioning of the device and correct placement. Intraoperative C-arm imaging is also routinely performed before the patient is extubated to confirm correct positioning of the implant. Any malpositioning or kinking of the electrode array, if detected, can be corrected immediately during the same operative setting, thus avoiding the need for a revision surgery later. A check X-ray is performed before the patient is discharged from the hospital, one copy of which is given to the patient and the other retained with the hospital for documentation. In case of any device migration or displacement in the future, this X-ray can act as a baseline for comparison.

Conclusion

The cortical mastoidectomy–posterior tympanotomy technique for cochlear implants has been successfully used by us. In spite of not using tie-down holes and tying down the receiver–stimulator with sutures, no cases of receiver–stimulator displacement or outward electrode migration have been noted with the current technique of creating a snug-fitting subperiosteal pocket along with a hook for the electrode array.

Adhering to a strict intraoperative surgical protocol plays an extremely important role in carrying out successful cochlear implant surgeries with minimal complications.

Conflict of Interest

None of the authors have any financial or nonfinancial conflict relevant to the article.

References

- 1 Mangus B, Rivas A, Tsai BS, Haynes DS, Roland JT Jr. Surgical techniques in cochlear implants. *Otolaryngol Clin North Am* 2012;45(1):69–80
- 2 Lee DJ, Driver M. Cochlear implant fixation using titanium screws. *Laryngoscope* 2005;115(5):910–911
- 3 Davis BM, Labadie RF, McMenomey SO, Haynes DS. Cochlear implant fixation using polypropylene mesh and titanium screws. *Laryngoscope* 2004;114(12):2116–2118
- 4 Rüdell C, Zöllner W. Ionomeric cement—a bone glue for device fixation. *Ear Nose Throat J* 1994;73(3):189–191
- 5 Loh C, Jiang D, Dezso A, Fitzgerald O'Connor A. Non-sutured fixation of cochlear implants using a minimally-invasive approach. *Clin Otolaryngol* 2008;33(3):259–261
- 6 Molony TB, Giles JE, Thompson TL, Motamedi KK; MD. Device fixation in cochlear implantation: is bone anchoring necessary? *Laryngoscope* 2010;120(9):1837–1839
- 7 Balkany TJ, Whitley M, Shapira Y, et al. The temporalis pocket technique for cochlear implantation: an anatomic and clinical study. *Otol Neurotol* 2009;30(7):903–907
- 8 Balkany T, Telischi FF. Fixation of the electrode cable during cochlear implantation: the split bridge technique. *Laryngoscope* 1995;105(2):217–218
- 9 Cohen NL, Kuzma J. Titanium clip for cochlear implant electrode fixation. *Ann Otol Rhinol Laryngol Suppl* 1995;166:402–403
- 10 Connell SS, Balkany TJ, Hodges AV, Telischi FF, Angeli SI, Eshraghi AA. Electrode migration after cochlear implantation. *Otol Neurotol* 2008;29(2):156–159