



The Clinical Spectrum of Patients of Horizontal Semicircular Canal Benign Paroxysmal Positional Vertigo Attending an Otoneurology Center in South Rajasthan, India and Their Response to Appropriate Repositioning Maneuvers at a Short-Term Follow-Up

Ajay Kumar Vats¹

¹Division of Medicine, Department of Neurology, Chaudhary Hospital and Medical Research Centre Private Limited, Udaipur, Rajasthan, India

Address for correspondence Ajay Kumar Vats, MBBS, MD, DM, Division of Medicine, Department of Neurology, Chaudhary Hospital and Medical Research Centre Private Limited, 472-473, Sector 4, Hiran Magri, Udaipur, Rajasthan 313002, India (e-mail: vatsneuro@gmail.com).

Ann Otol Neurotol:2021;3:61–71

Abstract

Keywords

- ▶ *geo*-HSC-BPPV
- ▶ *apo*-HSC-BPPV
- ▶ otoconial debris
- ▶ canalolithiasis
- ▶ cupulolithiasis
- ▶ supine roll test
- ▶ Gufoni maneuver
- ▶ Appiani maneuver
- ▶ barbecue roll maneuver
- ▶ head-shaking maneuver
- ▶ geotropic
- ▶ apogeotropic

Introduction This article aims to study the clinical spectrum of 20 consecutive patients diagnosed with horizontal semicircular canal benign paroxysmal positional vertigo (HSC-BPPV) attending an otoneurology center in Udaipur, Rajasthan, India, over a period of 11 months and their response to appropriate repositioning maneuvers evaluated at short-term follow-up of 1 hour and 24 hours.

Study Design This is a nonrandomized prospective interventional study.

Materials and Methods Twenty patients with unilateral HSC-BPPV were treated with a session of an appropriate repositioning maneuver (Gufoni maneuver or barbecue roll maneuver for the geotropic variant of HSC-BPPV [*geo*-HSC-BPPV]; Appiani maneuver or barbecue roll maneuver or head-shaking maneuver for the apogeotropic variant of the HSC-BPPV [*apo*-HSC-BPPV]). Patients were followed up twice (at 1 hour and 24 hours) and audited by a supine roll test with questioning for the absence or presence of concomitant vertigo.

Results At the 1-hour follow-up, 78.57% (11/14) patients of *geo*-HSC-BPPV treated with Gufoni maneuver recovered, and 66.67% (4/6) patients of *apo*-HSC-BPPV treated with some form of physical therapy recovered. The recovery was maintained at 24 hours' follow-up in both groups.

Conclusion To the best of the author's knowledge, no such study on patients of HSC-BPPV has been reported from India hitherto. Gufoni maneuver is an effective and safe treatment for the *geo*-HSC-BPPV with a recovery rate of 78.57% (11/14) at a short-term follow-up. The physical therapy for the *apo*-HSC-BPPV must be tailored according to the purported site of pathology which cannot be precisely predetermined most of the times.

Published online
August 23, 2020

DOI <https://doi.org/10.1055/s-0040-1715533>
ISSN 2581-9607.

©2020. Indian Society of Otolaryngology.

This is an open access article published by Thieme under the terms of the Creative Commons Attribution-NonDerivative-NonCommercial-License, permitting copying and reproduction so long as the original work is given appropriate credit. Contents may not be used for commercial purposes, or adapted, remixed, transformed or built upon. (<https://creativecommons.org/licenses/by-nc-nd/4.0/>).

Thieme Medical and Scientific Publishers Pvt. Ltd. A-12, 2nd Floor, Sector 2, Noida-201301 UP, India

Introduction

Benign paroxysmal positional vertigo (BPPV) is a mechanical disorder of the vestibular labyrinth, characterized by a sudden transient sensation of illusory spinning, when the head changes its position relative to the gravity. It is diagnosed by characteristic oculomotor patterns (positional nystagmus) elicited on the positional tests that localize and lateralize the involved semicircular canal as per the Ewald's three laws.¹ The typical situations triggering the vertigo paroxysms in BPPV are lying in the bed, taking lateral recumbent positions, getting up from supine to sitting position, stooping forward (e.g., tying shoelaces), and extending the neck (e.g., placing objects on a high shelf). The motion of head in a direction normally moves the endolymph within the semicircular canal aligned in the direction of head movement, bending the cupula to generate an appropriate nerve impulse, which apprises the brain via vestibulo-ocular reflex (VOR), the plane and the angle the head has moved. The brain reflexively (via VOR) makes corrective eye movements equal in angle, but the opposite direction and the point of fixation thereupon always falls on the fovea centralis. BPPV is frequently due to the inappropriate entry of the free-floating otoconial debris into one or more of three semicircular canals from the utricle, which is called canalolithiasis. Infrequently it is caused by the cupulolithiasis, in which otoconial debris becomes adherent to the cupula. With such pathologies, there is cupular deflection when the head moves to a certain position. This is secondary to the hydrodynamic drag of the endolymph in canalolithiasis and the cupula becoming heavier in cupulolithiasis. Deflection of cupula by the hydrodynamic drag of the free-floating otoconial debris or a heavy gravity-dependent cupula causes asymmetrical stimulation of the vestibular labyrinth in situations when the head moves relative to the gravity, which explains the symptom of positionally triggered vertigo.

–**Table 1** shows that 1.94 to 38% of all BPPV patients diagnosed at any specialty clinic have horizontal semicircular canal BPPV (HSC-BPPV).²⁻¹² Evidently, HSC-BPPV is

less common than the posterior semicircular canal BPPV (PSC-BPPV).

The HSC-BPPV is caused by the otoconial debris either free-floating within the arms, commonly long posterior (nonampullary) arm and less commonly short anterior (ampullary) arm of HSC (canalolithiasis), or else becoming adherent to the cupula (cupulolithiasis) on the canal side (Cup-C) or utricular side (Cup-U).¹³

The core symptom of HSC-BPPV is severe vertigo on lying supine as well as on rolling to either of the lateral recumbent positions. The associated autonomic symptoms like sweating, nausea, and vomiting are more severe in HSC-BPPV as compared with PSC-BPPV.¹⁴ The PSC slopes inferiorly and has its cupular barrier at a relatively more dependent end; any otoconial debris that sequesters in the ampullary arm of the PSC is liable to remain trapped for a long time. By comparison, the cupular barrier of the HSC is relatively higher in location allowing free-floating debris to easily drift back to the utricle under the effect of gravity, and it is, for this reason, spontaneous remissions are more frequent in patients with HSC-BPPV compared with those having PSC-BPPV.^{7,15}

A nonrandomized prospective interventional study of 20 consecutive patients diagnosed with HSC-BPPV at an otoneurology center in Udaipur, Rajasthan, India, was undertaken from December 29, 2018 to November 19, 2019. The patients were reevaluated at a short-term follow-up (at 1 and 24 hours) after an appropriate therapeutic repositioning maneuver. The short-term follow-up after therapeutic repositioning maneuver was aimed to minimize the confounding effects of spontaneous remissions reported in HSC-BPPV.^{7,15} To the best of the author's knowledge, no such study of patients diagnosed with HSC-BPPV has been reported from India hitherto.

Materials and Methods

This study was approved by the ethics committee of the attending otoneurology center. The HSC-BPPV was diagnosed as per the following criteria:

Table 1 Table showing the frequency of different variants of benign paroxysmal positional vertigo attending a specialty clinic

Authors	No. of patients	PSC-BPPV	HSC-BPPV	ASC-BPPV	Multiple canals
De la Meilleure et al ² 1996	287	78.05%	16.38%	–	5.57%
Honrubia et al ³ 1999	292	85.62%	5.14%	1.37%	7.87%
Macias et al ⁴ 2000	259	93.02%	1.94%	–	5.04%
Korres et al ⁵ 2002	122	90.16%	8.2%	1.64%	–
Sakaida et al ⁶ 2003	50	56%	38%	–	6%
Imai et al ⁷ 2005	108	64.82%	33.33%	–	1.85%
Nakayama and Epley, ⁸ 2005	833	66.39%	10.08%	2.28%	21.25%
Cakir et al ⁹ 2006	169	85.21%	11.83%	1.18%	1.78%
Moon et al ¹⁰ 2006	1,692	60.9%	31.9%	2.2%	5.0%
Jackson et al ¹¹ 2007	260	66.9%	11.9%	21.2%	–
Chung et al ¹² 2009	589	61.8%	35.3%	2.9%	–

Abbreviations: ASC-BPPV, anterior semicircular canal benign paroxysmal positional vertigo; HSC-BPPV, horizontal semicircular canal benign paroxysmal positional vertigo; PSC-BPPV, posterior semicircular canal benign paroxysmal positional vertigo.

- Rotational vertigo triggered by changes in the position of head relative to the gravity.
- Geotropic or apogeotropic horizontal positional nystagmus elicited by the supine head roll test, the side with stronger nystagmus in the geotropic variant and with weaker nystagmus in the apogeotropic variant was considered pathological as per Ewald's second law.¹
- Vertigo associated with the concomitant elicited positional nystagmus.
- Multi-canalicular BPPV cases included provided that one HSC was involved.

Exclusion criteria were: BPPV treated with repositioning maneuvers at any time in the past, posttraumatic BPPV, diagnosis of other peripheral vestibular disorders (Meniere's disease, vestibular neuritis, vestibular paroxysmia, etc.), and vertigo secondary to central nervous system disorders.

Informed consent was taken from all participants. The pathological side was identified by the supine head roll test.¹⁶ The supine roll test is done with the patient in long-sitting on the examination table. The patient is positioned supine from long-sitting on the examination table such that the head lays on a four-inch-thick pillow in 30 degrees of anteflexion. The supine neutral position is maintained for 30 seconds to look for lying-down nystagmus (LDN). Thereupon, the patient's

head is briskly rotated first to one side and maintained until the elicited positional nystagmus lasts. After the maximal head yawing on one side, the patient's head is brought to the neutral supine position and then briskly yawed to the other side, and maintained until the elicited positional nystagmus lasts. The supine roll test was performed multiple times (average five times at an interval of 5 minutes) in patients with apogeotropic positional nystagmus to look for any transformation to the geotropic variant.

Approximately 1 and 24 hours after a therapeutic maneuver, a verifying supine roll test was repeated to assess its outcome. The recovery was audited in terms of the disappearance of vertigo as well as the previously observed diagnostic positional nystagmus. No more than two different therapeutic maneuvers were performed in a single day, and the patient requiring a third maneuver was instructed to present the very next day. The applied therapeutic positional maneuvers were as under:

*Gufoni maneuver*¹⁷ (► Fig. 1) for the geotropic HSC-BPPV is performed by instructing the patient to sit on the edge of the examination table with both lower limbs hanging down. A brisk positioning from short-sitting to the contralateral lateral recumbent position is done and maintained for 1 minute (step 1). Thereupon, the patient's head is rotated approximately 45 degrees downwards in the yaw axis and maintained

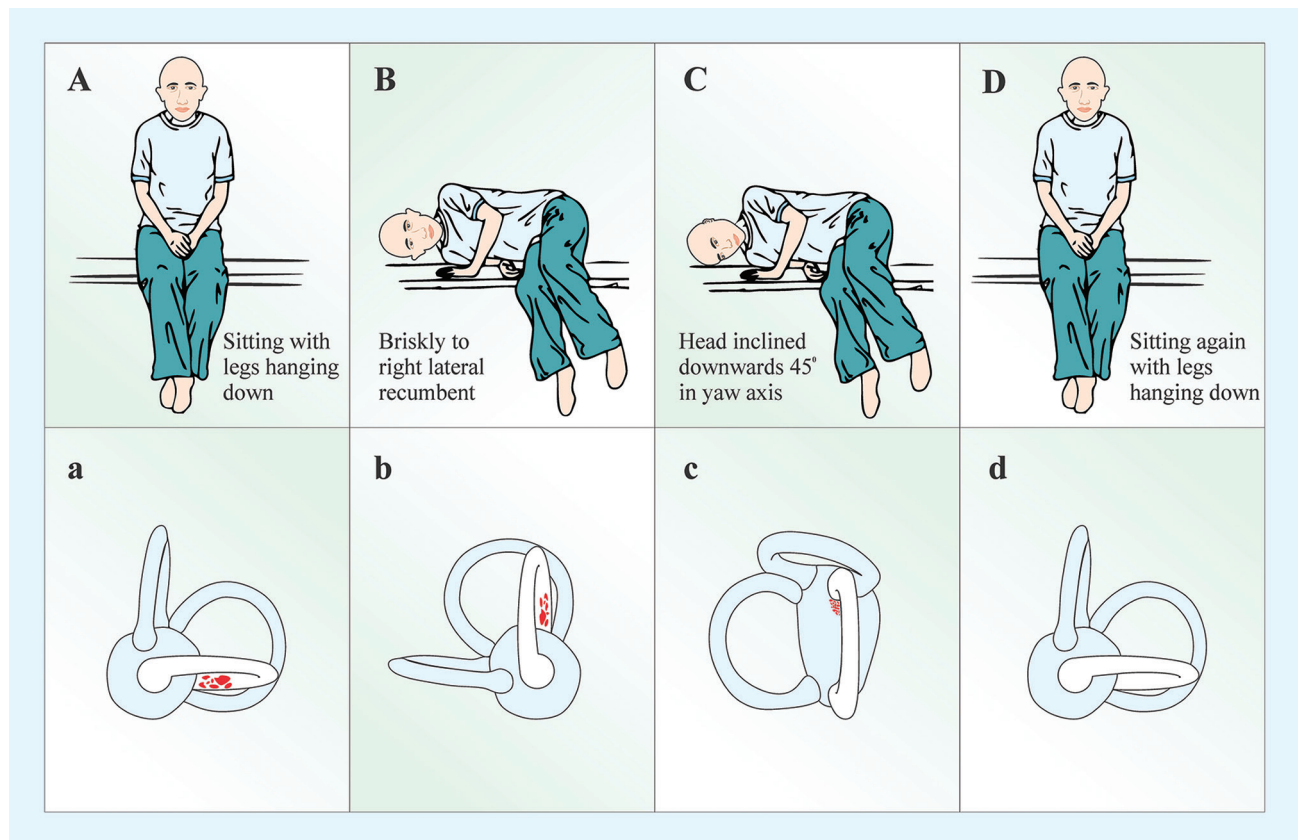


Fig. 1 Gufoni maneuver for the left posterior arm horizontal semicircular canalolithiasis. (A) The patient is placed in short sitting on the examination table with lower limbs hanging down. (B) Briskly positioned to the contralateral right lateral recumbent on the examination table and the position maintained for 1 minute. (C) The head is rotated 45 degrees downwards in the yaw-axis, and this position is maintained for 2 minutes. (D) Upright short sitting positioning is done. The lower panels a, b, c, and d show the transit of otoconial debris (in red) from the posterior arm of the left horizontal semicircular canal to the utricle during the maneuver.

for 2 minutes (step 2), after which upright positioning to the short sitting is done. Two sequent maneuvers are done in one session of treatment. Due to ease of performance and benignity, the Gufoni maneuver is the treatment of choice in the patients with a geotropic variant of HSC-BPPV.

Appiani maneuver¹⁸ (→Fig. 2) for the apogeotropic variant of HSC-BPPV is performed by instructing the patient to sit on the edge of the examination table with both lower limbs hanging down. A brisk positioning from short-sitting to the ipsilesional lateral recumbent position is done and maintained for 1 minute (step 1). Thereupon, the patient's head is rotated approximately 45 degrees upwards in the yaw axis and maintained for 2 minutes (step 2), after which upright positioning to the short sitting is done. Two sequent maneuvers are done in one session of treatment. Due to ease of performance and benignity, the Appiani maneuver is the treatment of choice in patients with an apogeotropic variant of HSC-BPPV.

Barbecue roll maneuver¹⁹: The patient is first positioned in the lateral recumbent position (the side with stronger horizontal positional nystagmus in the geotropic variant and with weaker horizontal positional nystagmus in the apogeotropic variant is the starting side), for approximately 30 seconds. Thereupon, the patient is rolled sequentially toward the uninvolved side, maintaining 30 seconds in each of the supine, opposite lateral recumbent, prone, and finally starting lateral recumbent positions. After completing one barbecue roll, the patient is positioned to upright sitting with lower limbs hanging down the long edge of the examination

table. Barbecue roll maneuver is performed six times consecutively (until two successive maneuvers are free of horizontal positional nystagmus during the right and left lateral recumbent positioning). Because it is difficult in patients with comorbid conditions like obesity, adhesive capsulitis of shoulder joint, and osteoarthritis of the knee to roll 360 degrees on the examination table, the barbecue roll maneuver is a second-choice treatment in patients with HSC-BPPV.

Head-shaking maneuver²⁰ (→Fig. 3) is performed with the patient in short-sitting and lower limbs hanging along the long edge of the examination table. The head is ante-flexed 30 degrees in the pitch plane and briskly shaken by the excursions of 30 degrees side-to-side in the yaw axis for around 30 seconds. Two sequent head-shaking maneuvers are done in one session of treatment. The head-shaking maneuver is chosen to treat patients with apogeotropic horizontal positional nystagmus, lasting more than a minute that did not change with multiple supine roll tests implying cupulolithiasis.

Epley maneuver (patient number 5 and 14): For the right Epley maneuver patient is positioned on the examination table in the long sitting such that the patient's left side is toward its free edge. The distance between the bottom of the patient and the head end of the table leaves a space for the head to hang as the patient is taken to the right Dix-Hallpike position. The patient's head is held with both hands and rotated 45 degrees to his/her right in the yaw axis. Thereupon, the patient is positioned supine in such a manner that the 45 degrees of right rotated head is extended

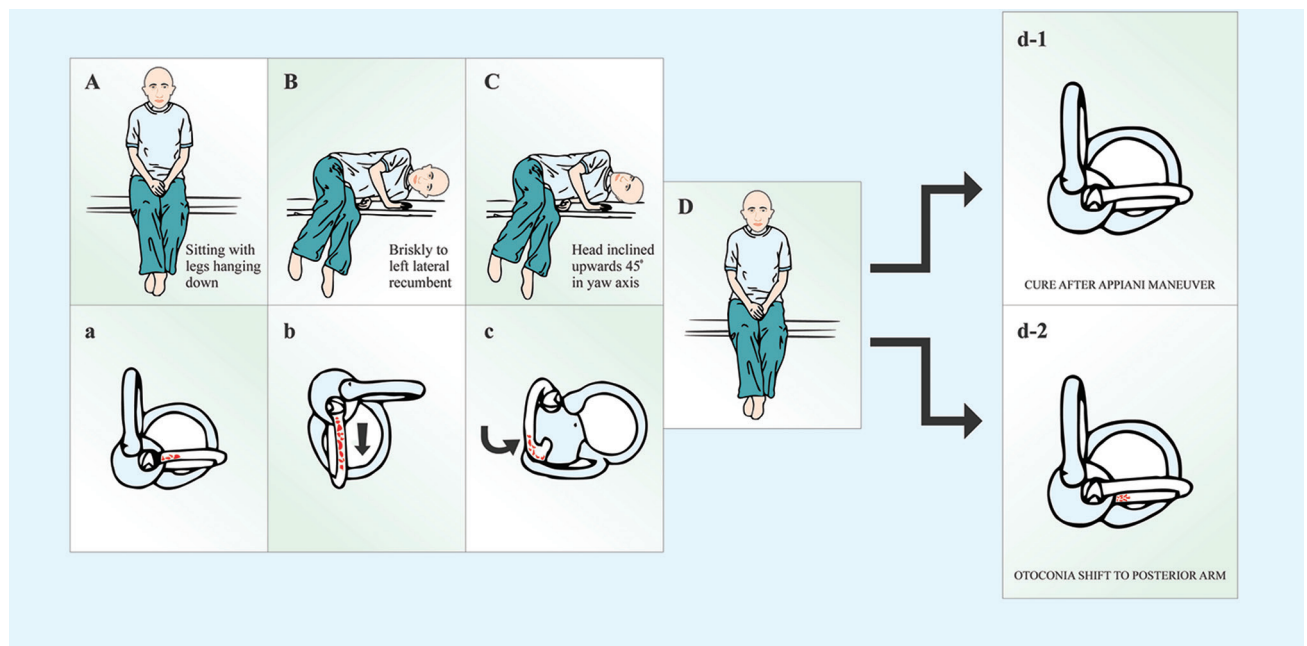


Fig. 2 Appiani maneuver for the left anterior arm horizontal semicircular canalolithiasis. (A) The patient is placed in short sitting on the examination table with lower limbs hanging down. (B) Briskly positioned to the ipsilesional left lateral recumbent on the examination table and the position maintained for 1 minute. (C) The head is rotated 45 degrees upwards in the yaw-axis and this position is maintained for 2 minutes. (D) Upright short sitting positioning is done. The lower panels a, b, and c, show the transit of otoconial debris (*in red*) from the anterior arm of the left horizontal semicircular canal to the utricle during the maneuver. The possible outcomes of the Appiani maneuver are either the otoconial debris is repositioned to the utricle thus clearing the left horizontal semicircular canal (d-1) or shift of otoconial debris to the posterior arm of the left horizontal semicircular canal thus transforming to left posterior arm horizontal semicircular canalolithiasis (d-2).

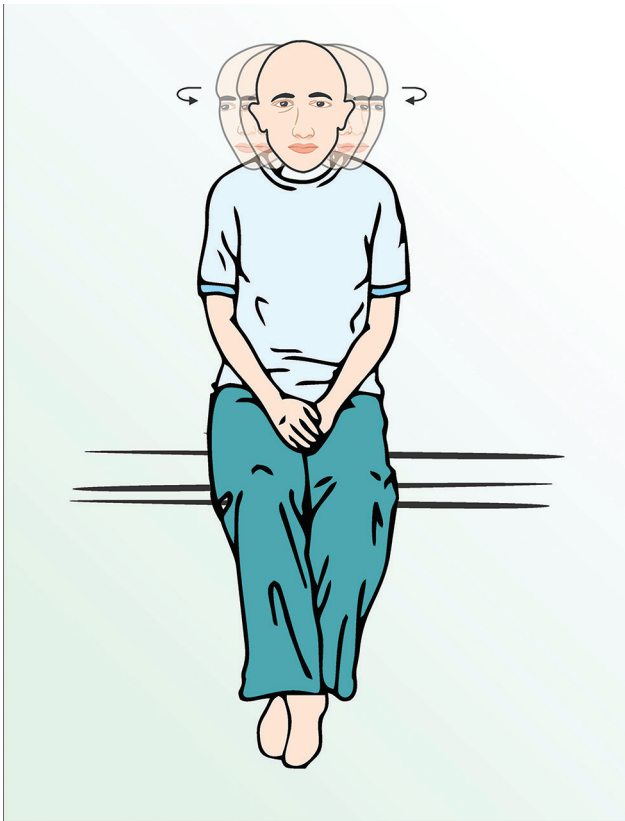

Fig. 3 Head-shaking maneuver is performed with the patient in short-sitting and lower limbs hanging along the long edge of the examination table. The head is anteflexed 30 degrees in the pitch plane and is briskly shaken by the excursions of 30 degrees side-to-side in the yaw axis for around 30 seconds.

20 degrees on the support of the author's hands to represent the right Dix–Hallpike position. In the right Dix–Hallpike position, the head is maintained for 60 seconds. Upon completion of 1 minute with 45 degrees of cervical rotation to the ipsilesional right side, the head is rotated 90 degrees in the rostral–caudal body axis to the patient's left, maintaining its 20 degrees extension. Positioning 45 degrees of cervical rotation from the sagittal plane to the contralesional left side with the neck in 20 degrees of an extension is maintained for 1 minute. Thereupon, left lateral recumbent positioning with nose oriented almost at right angles to the surface of the treatment table is done and maintained for 1 minute. Lastly, the patient is instructed to sequentially hang down lower limbs along the free edge of the examination table, and while maintaining the left rotated head position, the patient is positioned to the upright sitting completing Epley maneuver.

A therapeutic maneuver is deemed to have failed if a verifying supine roll test after 1 hour did not eliminate the positional nystagmus and vertigo observed during the initial diagnostic positional test. At 1-hour follow-up, on supine roll test, a change in the pattern of positional nystagmus from apogeotropic to geotropic or the other way around and canal switch to PSC-BPPV may be a harbinger of a favorable or unfavorable outcome but is deemed a recovery failure in this study.

Results

The demographic data of the patients are shown in ►Table 2. Patients included 11 (55%) women and 9 men (45%) with a women-to-men ratio of 1.2:1. Roughly 45% of patients were in the age group of 10 to 40 years, 50% in the range 41 to 70 years, and 5% above 70 years of age. The right ear was involved in 65% of cases (13/20), of which 69.23% were geotropic (9/13) and 30.77% (4/13) were apogeotropic variants. The left ear was involved in 35% of cases (7/20), of which 71.43% were geotropic (5/7) and 28.57% were apogeotropic (2/7). The supine roll test elicited an asymmetric horizontal positional nystagmus in all but one patient. The lateralization of the involved semicircular canal in patient number 3 with symmetrically strong geotropic horizontal positional nystagmus on the supine roll test was inferred from the direction of LDN.²¹ The duration of symptoms was less than a week in 70% (14/20), 1 to 2 weeks in 20% (4/20), and more than 2 weeks in 10% of patients (2/20). The clinical data of the patients relating to symptom duration, diagnostic supine roll test results, and the presence or absence of LDN are shown in ►Table 3. The data of the applied therapeutic maneuvers, results of the verifying supine roll test, and/or Dix–Hallpike test performed after 1 hour and after 24 hours of the therapeutic maneuver are shown in ►Table 4.

Geotropic Variant (*geo*-HSC-BPPV)

At the 1-hour follow-up, 78.57% (11/14) patients of *geo*-HSC-BPPV treated with Gufoni maneuver recovered. Two patients (patient number 6 and 12) of *geo*-HSC-BPPV treated with Gufoni maneuver transformed to *apo*-HSC-BPPV (►Fig. 4). Patient number 6 responded to a session of treatment with Appiani maneuver for the transformed *apo*-HSC-BPPV, and a verifying supine roll test 24 hours later neither elicited the positional nystagmus nor vertigo was complained by the patient. The patient number 12 failed to respond to the session of Appiani maneuver, with the verifying supine roll test

Table 2 Demographic characteristics of the patients diagnosed with HSC-BPPV

Serial no.	Demographic characteristics of the patients	
1.	Symptom duration	Number of patients
	< 1 wk	14
	1–2 wk	4
	> 2 wk	2
2.	Age (in y)	Number of patients
	10–40	9
	41–70	10
	71–90	1
3.	Sex ratio (M:F)	9:11
4.	Geotropic:Apogeotropic	14:6
5.	Right:Left	13:7

Abbreviation: HSC-BPPV, horizontal semicircular canal benign paroxysmal positional vertigo.

Table 3 The characteristics of diagnostic positional nystagmus elicited on the supine roll test on yawing the head to the right and left, and lying-down nystagmus (LDN) in the supine neutral position

Patient number	Age	Sex	Vertigo duration	Supine roll test				Diagnosis	LDN
				Geotropic		Apogeotropic			
				Right	Left	Right	Left		
1.	17	M	4 d	+	++	-	-	Left <i>geo</i> -HSC-BPPV	-
2.	52	F	7 d	-	-	+	++	Right <i>apo</i> -HSC-BPPV	-
3.	38	M	2 d	++	++	-	-	Left <i>geo</i> -HSC-BPPV	To right
4.	33	M	5 d	++	+	-	-	Right <i>geo</i> -HSC-BPPV	To left
5.	59	F	1 d	-	-	+	++	Right <i>apo</i> -HSC-BPPV	-
6.	50	F	10 d	++	+	-	-	Right <i>geo</i> -HSC-BPPV	-
7.	48	M	1 d	++	+	-	-	Right <i>geo</i> -HSC-BPPV	To right
8.	86	M	3 d	+	++	-	-	Left <i>geo</i> -HSC-BPPV	-
9.	40	F	1 d	-	-	+	++	Right <i>apo</i> -HSC-BPPV	-
10.	29	F	1 d	-	-	++	+	Left <i>apo</i> -HSC-BPPV	To left
11.	56	M	3 mo	-	-	+	++	Right <i>apo</i> -HSC-BPPV	-
12.	46	M	1 d	+	++	-	-	Left <i>geo</i> -HSC-BPPV	-
13.	43	F	3 d	++	+	-	-	Right <i>geo</i> -HSC-BPPV	To left
14.	70	M	1 d	++	+	-	-	Right <i>geo</i> -HSC-BPPV plus Right PSC-BPPV	To left
15.	31	F	2 d	++	+	-	-	Right <i>geo</i> -HSC-BPPV	-
16.	54	F	4 d	++	+	-	-	Right <i>geo</i> -HSC-BPPV	-
17.	34	M	1 d	++	+	-	-	Right <i>geo</i> -HSC-BPPV	-
18.	72	F	10 d	++	+	-	-	Right <i>geo</i> -HSC-BPPV	-
19.	25	F	8 d	-	-	++	+	Left <i>apo</i> -HSC-BPPV	-
20.	32	F	1 mo	+	++	-	-	Left <i>geo</i> -HSC-BPPV	-

Abbreviations: -, absent; +, weaker; ++, stronger; *apo*, apogeotropic; F, female; *geo*, geotropic; HSC-BPPV, horizontal semicircular canal benign paroxysmal position vertigo; LDN, lying-down nystagmus; M, male.

Note: The symptom duration along with demographic data, localization (diagnosis), and lateralization are also shown.

after 1 hour neither suppressing the apogeotropic horizontal positional nystagmus nor concomitant vertigo. Thereupon, he was treated with a session of barbecue roll maneuver the following day. A verifying supine roll test after another 24 hours did not elicit horizontal positional nystagmus and patient was free of vertigo. Patient number 14 was diagnosed with unilateral multi-canalicular BPPV involving right-sided horizontal and PSCs. His initial supine roll test elicited a horizontal LDN of 23 seconds duration, beating to the patient's left in the neutral supine position. The yawing of the head to the right initially elicited, after a latency of 5 seconds, a counterclockwise torsional (from examiner's perspective) upbeatting positional nystagmus lasting approximately 23 seconds. Subsequently, the patient's head was brought to the neutral supine position and then briskly yawed to his left, which after a latency of 2 seconds, elicited a geotropic horizontal positional nystagmus lasting 15 seconds. A repeat yawing of the head to the right elicited, after a latency of 2 seconds, a stronger geotropic horizontal positional nystagmus. He was initially treated with a session of Gufoni maneuver, and the

verifying supine roll test performed 1 hour later neither suppressed the geotropic positional nystagmus nor concomitant vertigo. Thereupon, a session of barbecue roll maneuver was performed and a supine roll test to the right, after 1 hour elicited upbeatting counterclockwise (from examiner's perspective) upbeatting positional nystagmus. The residual right posterior semicircular canalolithiasis was treated with a session of five consecutive right Epley maneuvers the next day. A verifying supine roll test and Dix-Hallpike test after an hour, and at 24 hours did not elicit either horizontal or upbeatting torsional positional nystagmus.

Apogeotropic Variant (*apo*-HSC-BPPV)

At the 1-hour follow-up, 66.67% (4/6) patients of *apo*-HSC-BPPV treated with some form of physical therapy recovered. The initial supine roll test of patient number 2 and patient number 10 elicited an asymmetric apogeotropic horizontal positional nystagmus lasting less than a minute, and a diagnosis of right and left *apo*-HSC-BPPV was established, based on the elicited weaker nystagmus on the right and left

Table 4 Efficacy of applied repositioning maneuvers in patients with horizontal semicircular canal benign paroxysmal positional vertigo at short-term follow-up at 1 hour and after 24 hours

Pt. no.	Diagnosis	Therapeutic maneuver (Day 1)	PN elicited on SRT after 1 h (Day 1)	PN elicited on SRT/DHT at 24 h (Day 2)
1.	Left <i>geo</i> -HSC-BPPV	GM	Negative	Negative
2.	Right <i>apo</i> -HSC-BPPV	During 2nd AM transformed to <i>geo</i> -HSC-BPPV followed by GM	Negative	Negative
3.	Left <i>geo</i> -HSC-BPPV	GM	Negative	Negative
4.	Right <i>geo</i> -HSC-BPPV	GM	Negative	Negative
5.	Right <i>apo</i> -HSC-BPPV	AM	UBN; treated with EM	SRT and DHT negative
6.	Right <i>geo</i> -HSC-BPPV	GM	Bilateral apogeotropic PN (L > R); treated with AM	–
7.	Right <i>geo</i> -HSC-BPPV	GM	Negative	Negative
8.	Left <i>geo</i> -HSC-BPPV	GM	Negative	Negative
9.	Right <i>apo</i> -HSC-BPPV	HSM	Negative	Negative
10.	Left <i>apo</i> -HSC-BPPV	AM	Bilateral geotropic (L > R); treated with GM ^a	Negative
11.	Right <i>apo</i> -HSC-BPPV	AM	Negative	Negative
12.	Left <i>geo</i> -HSC-BPPV	GM	Bilateral apogeotropic, R > L; treated with AM	Bilateral apogeotropic R > L: treated with barbecue roll maneuver
13.	Right <i>geo</i> -HSC-BPPV	GM	Negative	Negative
14.	Right <i>geo</i> -HSC-BPPV plus right PSC-BPPV	GM followed by Barbecue roll	Right SRT UBN; treated with EM	Negative
15.	Right <i>geo</i> -HSC-BPPV	GM	Negative	Negative
16.	Right <i>geo</i> -HSC-BPPV	GM	Negative	Negative
17.	Right <i>geo</i> -HSC-BPPV	GM	Negative	Negative
18.	Right <i>geo</i> -HSC-BPPV	GM	Negative	Negative
19.	Left <i>apo</i> -HSC-BPPV	HSM	Negative	Negative
20.	Left <i>geo</i> -HSC-BPPV	GM	Negative	Negative

Abbreviations: >, stronger than; AM, Appiani maneuver; *apo*, apogeotropic; DHT, Dix–Hallpike test; EM, Epley maneuver; *geo*, geotropic; GM, Gufoni maneuver; HSC-BPPV, horizontal semicircular canal benign paroxysmal position vertigo; HSM, head-shaking maneuver; L, left; PN, positional nystagmus; Pt. no., patient number; R, right; SRT, supine roll test; UBN, upbeating nystagmus.

^aVerifying SRT performed 12 minutes after the diagnostic SRT in the view of previous experience of transformation to *geo*-HSC-BPPV in patient number 2.

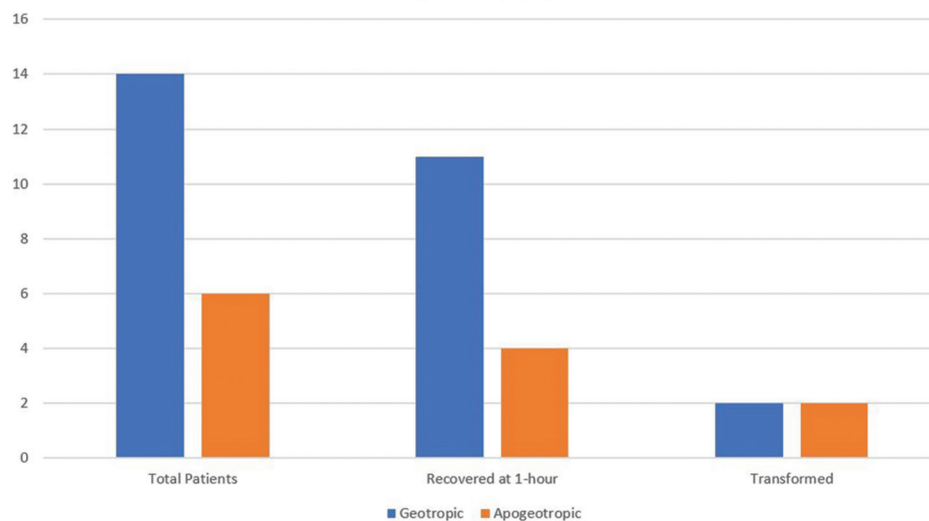


Fig. 4 Figure depicting the outcomes of therapeutic positioning maneuvers at 1-hour follow-up in patients of horizontal semicircular canal benign paroxysmal positional vertigo (HSC-BPPV). The *geo*-HSC-BPPV showed a higher rate of recovery at 1-hour with the Gufoni maneuver when compared with some form of physical therapy for the *apo*-HSC-BPPV. The transformation rate at 1-hour in the two variants was identical.

sides, respectively. Both patients (numbers 2 and 10) underwent therapeutic Appiani maneuvers with an intent to treat. Patient number 2 during the first step of Appiani maneuver and the patient number 10 twelve minutes after completion of the session of Appiani maneuver transformed to the *geo*-HSC-BPPV. During the step 1 of Appiani maneuver in patient number 10, the otoconial debris in the anterior arm of the left HSC (►Fig. 2A) apparently shifted toward its posterior end (►Fig. 2B) owing to the vertical orientation of canal and brisk deceleration. The 45 degrees upward inclination of the head in the yaw axis in the step 2 of the maneuver (►Fig. 2C) places the utricular exit in the nonampullary posterior long-arm of the left HSC to the most gravity-dependent position. The latter position was anticipated to further shift the otoconial debris in the posterior nonampullary arm of the left HSC, to facilitate its exit through the opening to the utricle, resulting in the direct resolution of the left *apo*-HSC-BPPV (►Fig. 2, d-1), but it did not work the way as it did in patient number 11. Instead, the Appiani maneuver in patient number 10 transformed the left anterior arm horizontal semicircular canalolithiasis (*apogeotropic*) to the left posterior arm horizontal semicircular canalolithiasis (*geotropic*), making it treatable by the better-established therapeutic options (►Videos 1–6). Likewise, in patient number 2, the step 1 of the second sequent Appiani maneuver transformed the right anterior arm horizontal semicircular canalolithiasis (*apogeotropic*) to the right posterior arm horizontal semicircular canalolithiasis (*geotropic*). The transformed *geo*-HSC-BPPV in patient number 2 and 10 was treated with a session of the Gufoni maneuver (►Fig. 1). A verifying supine roll test at 1 hour, and 24 hours after the Gufoni maneuver neither elicited positional nystagmus nor any concomitant vertigo. Patient number 5 was diagnosed with right *apo*-HSC-BPPV (right anterior arm horizontal semicircular canalolithiasis or right horizontal semicircular cupulolithiasis) based on the oculomotor findings on the supine roll test. Yawing the head of patient number 5 to the

Video 1

Positioning the patient number 10 from sitting to the supine neutral position elicits a strong lying-down nystagmus lasting approximately 30 seconds and beating to the patient's left. Online content including video sequences viewable at: <https://www.thieme-connect.com/products/ejournals/html/10.1055/s-0040-1715533>.

Video 2

Supine roll test of patient number 10 elicits an *apogeotropic* horizontal positional nystagmus on yawing the head maximally to the right as well as to the left, which is visibly stronger on the right. Online content including video sequences viewable at: <https://www.thieme-connect.com/products/ejournals/html/10.1055/s-0040-1715533>.

Video 3

Appiani maneuver is performed with the patient number 10 in short-sitting and her lower limbs hanging down the long edge of the examination table. From the upright short-sitting, a brisk left (*ipsilesional*) lateral recumbent positioning is done (step 1), and after a minute, the patient's head is inclined 45 degrees upwards in the yaw axis and maintained for 2 minutes (step 2). Thereupon, the patient is positioned upright in the short sitting, completing the Appiani maneuver. Online content including video sequences viewable at: <https://www.thieme-connect.com/products/ejournals/html/10.1055/s-0040-1715533>.

Video 4

The verifying supine roll test of patient number 10 elicits a *geotropic* horizontal positional nystagmus on yawing the head maximally to the right as well as to the left, which is visibly stronger on the left. Online content including video sequences viewable at: <https://www.thieme-connect.com/products/ejournals/html/10.1055/s-0040-1715533>.

Video 5

Gufoni maneuver for the transformed left *geo*-HSC-BPPV is performed by instructing the patient number 10 to be in short sitting with both lower limbs hanging down and briskly moving the patient to the right (*contralesional*) lateral recumbent position and maintaining the latter position for 1 minute (step 1). Thereupon, the patient's head is rotated approximately 45 degrees downwards in the yaw-axis and is maintained for 2 minutes (step 2), after which she is positioned upright to the short sitting. Online content including video sequences viewable at: <https://www.thieme-connect.com/products/ejournals/html/10.1055/s-0040-1715533>.

Video 6

The verifying supine roll test of the patient number 10 twenty-four hours after the Gufoni maneuver did not elicit any lying down nystagmus or horizontal positional nystagmus on maximal yawing of the head to the right and left and the patient did not complain of vertigo either. Online content including video sequences viewable at: <https://www.thieme-connect.com/products/ejournals/html/10.1055/s-0040-1715533>.

left elicited after a latency of 28 seconds, a stronger apogeotropic horizontal positional nystagmus lasting 30 seconds, and yawing to the right elicited after a latency of 4 seconds, a weaker apogeotropic horizontal positional nystagmus lasting 110 seconds. She was treated with a session of the Appiani maneuver. During the verifying supine roll test after 1 hour, yawing the head to the right elicited, after a latency of 3 seconds, an upbeating counterclockwise torsional (from the examiner's perspective) positional nystagmus implying transformation to the right PSC-BPPV. The patient was treated with a session of five Epley maneuvers and a verifying Dix–Hallpike test and supine roll test at 1 hour and after 24 hours neither elicited positional nystagmus nor concomitant vertigo. Because the patient number 2, 5, and 10 were either transformable to geotropic variant (patient number 2 and 10) or the PSC-BPPV (►Fig. 4) and the patient number 11 directly resolved with Appiani maneuver (similar to ►Fig. 2, d-1, but lateralization to right), in all probability, these four patients with *apo*-HSC-BPPV were suffering from the short anterior-arm horizontal semicircular canalolithiasis.

Two patients with *apo*-HSC-BPPV (patient numbers 9 and 19) in all probability suffered from cupulolithiasis as the horizontal positional nystagmus elicited during the supine roll test lasted more than a minute and did not change on repeat testing several times. The details of supine roll test in these two patients are as under:

Patient number 9: During the supine roll test, yawing the head of the patient number 9 to the left, elicited after a latency of 5 seconds stronger apogeotropic horizontal positional nystagmus that lasted 173 seconds (till the time head remained yawed to the left), and yawing the head to the right elicited after a latency of 4 seconds, a weaker apogeotropic horizontal positional nystagmus that lasted 47 seconds.

Patient number 19 (►Videos 7–9): During the supine roll test (►Video 7), yawing the head of the patient number 19 to the right, elicited after a latency of 4 seconds, a stronger apogeotropic horizontal positional nystagmus that lasted 190 seconds (till the time head remained yawed to the right), and yawing the head to the left elicited after a latency of

Video 7

Supine roll test of patient number 19 elicits an apogeotropic horizontal positional nystagmus on yawing the head maximally to the right as well as to the left, which is visibly stronger on the right. The latency of the apogeotropic horizontal positional nystagmus is 4 seconds on either side, and its duration is 190 seconds on the right and 60 seconds on the left side. The characteristics of the apogeotropic horizontal positional nystagmus did not change during several cycles of the diagnostic supine roll test, implying in all probability a pathology of left horizontal semicircular cupulolithiasis. Online content including video sequences viewable at: <https://www.thieme-connect.com/products/ejournals/html/10.1055/s-0040-1715533>.

Video 8

Head-shaking maneuver is performed with the patient number 19 in short-sitting and lower limbs hanging along the long edge of the examination table. The head is anteflexed 30 degrees in the pitch plane and briskly shaken by the excursions of 30 degrees side-to-side in the yaw axis for around 30 seconds. Online content including video sequences viewable at: <https://www.thieme-connect.com/products/ejournals/html/10.1055/s-0040-1715533>.

Video 9

The verifying supine roll test of patient number 19 performed an hour after the head-shaking maneuver did not elicit any lying-down nystagmus or horizontal positional nystagmus on maximal yawing of the head to the right and left and the patient did not complain of vertigo either. Online content including video sequences viewable at: <https://www.thieme-connect.com/products/ejournals/html/10.1055/s-0040-1715533>.

4 seconds, a weaker apogeotropic horizontal positional nystagmus that lasted 60 seconds.

Both were treated with a session of head-shaking maneuver (►Fig. 3). A verifying supine roll test at 1 hour, and 24 hours after the head-shaking maneuver neither elicited positional nystagmus nor any concomitant vertigo in patient numbers 9 and 19. Because the supine roll test elicited a very long duration unchanging apogeotropic horizontal positional nystagmus in the patient number 9 and 19, in all probability, these two were suffering from cupulolithiasis. The very fact that the long duration apogeotropic horizontal positional nystagmus disappeared on verifying supine roll test performed 1 hour after the therapeutic head-shaking maneuver implies that the cupulolithiasis was to the utricular side of the cupula (Cup-U).

LDN was observed in 30% (6/20) of patients, of which 5 were *geo*-HSC-BPPV and 1 *apo*-HSC-BPPV. In 80% (4/5) patients with *geo*-HSC-BPPV, LDN was directed opposite to the involved side (paradigmatic), and in 20% (1/5) toward the involved side (nonparadigmatic). Only 16.67% (1/6) patients with *apo*-HSC-BPPV had LDN, which was paradigmatic.

Discussion

The HSC-BPPV exists in two variants, a much responsive geotropic and a potentially difficult to treat apogeotropic variant. Since the sole pathology responsible for the *geo*-HSC-BPPV is the presence of free-floating otoconial debris, localized exclusively to the long posterior nonampullary arm of the HSC, the explicit goal of treatment is repositioning it back to the utricle employing some form of physical

therapy. By comparison, the *apo*-HSC-BPPV could be due to either short anterior ampullary arm canalolithiasis or cupulolithiasis (Cup-C or Cup-U), and the exact pathological site cannot be precisely predetermined by any means. However, in the short anterior arm canalolithiasis, a transformation from apogeotropic to geotropic positional nystagmus can be observed during diagnostic positional or therapeutic maneuvers (►Fig. 2, ►Videos 1–6).^{18,22–25} The apogeotropic horizontal positional nystagmus, which lasts for more than 1 minute and does not change even after several cycles of the supine roll test, is in all probability due to cupulolithiasis.²⁶

The effects of the therapeutic positional maneuver in this study were audited by two short-term follow-ups (at 1 hour and 24 hours), to exclude the confounding effect of spontaneous remission of HSC-BPPV reported in some studies.^{7,15} The Gufoni maneuver proved highly effective in the treatment of *geo*-HSC-BPPV with recovery in 78.57% at 1-hour follow-up, which was maintained at 24 hours. By comparison, 66.67% of patients (patient number 2, 9, 11, and 19) with *apo*-HSC-BPPV who underwent some form of physical therapy recovered at 1-hour follow-up, and this was maintained at 24 hours. The heterogeneity in the clinical spectrum of *apo*-HSC-BPPV, especially when it comes to the available treatment options, is attributed to the multitude of pathologies resulting in elicitation of an identical oculomotor pattern on the diagnostic supine roll test, namely the apogeotropic horizontal positional nystagmus. The transformation of *apo*-HSC-BPPV to *geo*-HSC-BPPV and vice versa was 10% in this study, which is identical to that reported in one previous study.²⁷ In 33.33% of *apo*-HSC-BPPV patients, transformation to a variant (to PSC-BPPV in patient number 5 and the *geo*-HSC-BPPV in patient number 10) with better-established treatment options resulted in recovery at 24 hours. The case of unilateral multi-canalicular vestibular lithiasis of right horizontal and PSCs (patient number 14), due to its inherent nature required different maneuvers to clear the affected horizontal and PSCs.

Conclusion

This prospective nonrandomized interventional study concludes that the Gufoni maneuver is an effective and safe treatment for the *geo*-HSC-BPPV with recovery rate of 78.57% at a short-term follow-up. The physical therapy for the *apo*-HSC-BPPV must be tailored according to the purported site of pathology which cannot be precisely predetermined most of the times. Many patients with *apo*-HSC-BPPV, especially those with short anterior ampullary arm canalolithiasis are commutable to either *geo*-HSC-BPPV or PSC-BPPV with better established treatment options. Offloading the heavy cupula in the Cup-U variant of the cupulolithiasis, by detaching the otoconial debris adherent to utricular side of the cupula by briskly shaking the head in yaw axis with the head pitched 30 degrees in anteflexion (►Fig. 3) can sometimes bring immediate recovery.

Note

The views expressed in the submitted article are author's own and not an official position of the institution to which the author is affiliated.

Conflict of Interest

None declared.

Acknowledgments

The authors would like to thank Mr. Renith Kurian, who video recorded the diagnostic and therapeutic maneuvers and precisely captured the nystagmus during the entire diagnostic and treatment period and to Mr. Ashraf Hussain for drawing the ►Figs. 1–3 on CorelDraw graphics suite 2019.

References

- 1 Ewald JR, Physiologische Untersuchungen Ueber das Endorgan de Nervus Octavus. Wiesbaden, Germany: Bergmann JF Publishers;1892
- 2 De la Meilleure G, Dehaene I, Depondt M, Damman W, Crevits L, Vanhooren G. BPPV of the horizontal canal. J Neurol Neurosurg Psychiatry 1996;60(1):68–71
- 3 Honrubia V, Baloh RW, Harris MR, Jacobson KM. Paroxysmal positional vertigo syndrome. Am J Otol 1999;20(4):465–470
- 4 Macias JD, Lambert KM, Massingale S, Ellensohn A, Fritz JA. Variables affecting treatment in BPPV. Laryngoscope 2000;110(11):1921–1924
- 5 Korres S, Balatsouras DG, Kaberos A, Economou C, Kandiloros D, Ferekidis E. Occurrence of semicircular canal involvement in BPPV. Otol Neurotol 2002;23(6):926–932
- 6 Sakaida M, Takeuchi K, Ishinaga H, Adachi M, Majima Y. Long-term outcome of BPPV. Neurology 2003;60(9):1532–1534
- 7 Imai T, Ito M, Takeda N, et al. Natural course of the remission of vertigo in patients with BPPV. Neurology 2005;64(5):920–921
- 8 Nakayama M, Epley JM. BPPV and variants: improved treatment results with automated, nystagmus-based repositioning. Otolaryngol Head Neck Surg 2005;133(1):107–112
- 9 Cakir BO, Ercan I, Cakir ZA, Civelek S, Sayin I, Turgut S. What is the true incidence of horizontal semicircular canal BPPV. Otolaryngol Head Neck Surg 2006;134(3):451–454
- 10 Moon SY, Kim JS, Kim BK, et al. Clinical characteristics of BPPV in Korea: a multicenter study. J Korean Med Sci 2006;21(3):539–543
- 11 Jackson LE, Morgan B, Fletcher JC, Krueger WW. Anterior canal BPPV: an underappreciated entity. Otol Neurotol 2007;28(2):218–222
- 12 Chung KW, Park KN, Ko MH, et al. Incidence of horizontal canal BPPV as a function of the duration of symptoms. Otol Neurotol 2009;30(2):202–205
- 13 Brintjes TD, Masius-Olthof S, Kingma H. Benign paroxysmal positional vertigo of the horizontal canal. Clin Otorhinolaryngol 2017;1:1–7
- 14 Pagnini P, Nuti D, Vannucchi P. Benign paroxysmal vertigo of the horizontal canal. ORL J Otorhinolaryngol Relat Spec 1989;51(3):161–170
- 15 Parnes LS, Agrawal SK, Atlas J. Diagnosis and management of benign paroxysmal positional vertigo (BPPV) CMAJ 2003;169(7):681–693
- 16 Lee SH, Kim JS. Benign paroxysmal positional vertigo. J Clin Neurol 2010;6(2):51–63
- 17 Ciniglio Appiani G, Catania G, Gagliardi M. A liberatory maneuver for the treatment of horizontal canal paroxysmal positional vertigo. Otol Neurotol 2001;22(1):66–69

- 18 Ciniglio Appiani G, Catania G, Gagliardi M, Cuiuli G. Repositioning maneuver for the treatment of the apogeotropic variant of horizontal canal benign paroxysmal positional vertigo. *Otol Neurotol* 2005;26(2):257-260
- 19 Tusa RJ. Vertigo. *Neurol Clin* 2001;19(1):23-55
- 20 Kim JS, Oh SY, Lee SH, et al. Randomized clinical trial for apogeotropic horizontal canal benign paroxysmal positional vertigo. *Neurology* 2012;78(3):159-166
- 21 Han BI, Oh HJ, Kim JS. Nystagmus while recumbent in horizontal canal benign paroxysmal positional vertigo. *Neurology* 2006;66(5):706-710
- 22 Nuti D, Vannucchi P, Pagnini P. Benign paroxysmal positional vertigo of the horizontal canal: a form of canalolithiasis with variable clinical features. *J Vestib Res* 1996;6(3):173-184
- 23 Casani AP, Vannucci G, Fattori B, Berrettini S. The treatment of horizontal canal positional vertigo: our experience in 66 cases. *Laryngoscope* 2002;112(1):172-178
- 24 Asprella Libonati G. Diagnostic and treatment strategy of lateral semicircular canal canalolithiasis. *Acta Otorhinolaryngol Ital* 2005;25(5):277-283
- 25 Vannucchi P, Asprella Libonati G, Gufoni M. The physical treatment of lateral semicircular canal canalolithiasis. *Audiol Med* 2005;3:52-56
- 26 von Brevern M, Bertholon P, Brandt T, et al. Benign paroxysmal positional vertigo: diagnostic criteria. *J Vestib Res* 2015;25(3-4):105-117
- 27 Mandalà M, Pepponi E, Santoro GP, et al. Double-blind randomized trial on the efficacy of the Gufoni maneuver for treatment of lateral canal BPPV. *Laryngoscope* 2013;123(7):1782-1786